



Lemierre Syndrome in a Pediatric Patient with Nephrotic Syndrome: A Case Report

Chady El Tawil^{1,2}, Anwar Alabdulraheem², Keira Kilmartin^{2,3}, Jade Seguin^{1,2}

ABSTRACT

Lemierre syndrome is a rare thrombotic complication of head and neck infections. Nephrotic syndrome is sometimes treated by immunosuppressive medications that can present with severe infections without a fever. The association of the two diseases is extremely rare.

We report the first case, to our knowledge, of Lemierre syndrome in an eleven-year-old patient with nephrotic syndrome on Tacrolimus.

A patient with nephrotic syndrome is at higher risk for all kinds of thrombotic events. Also, being on immunosuppressive therapy can lead to late presentation and the absence of fever. A low level of suspicion in those patients can lead to timely diagnosis and early treatment.

INTRODUCTION

Lemierre syndrome (LS) is a rare complication of head and neck infections in the pediatric population. Classically the syndrome consists of suppurative thrombophlebitis of the internal jugular veins secondary to infection of the oropharynx with *Fusobacterium necrophorum* bacteremia [1]. The bacterial pharyngitis is usually seen with peritonsillar abscess which can rupture and spread to the carotid sheath that contains the internal carotid artery and internal jugular vein. This leads to seeding of the internal jugular vein with bacteria and the formation of thrombophlebitis which can then spread systemically. Typical presentation includes recent oropharyngeal symptoms which may resolve followed by progression to high fever, headache, neck pain, and respiratory symptoms [2]. Infection may occur in previously healthy children and in individuals with chronic conditions such as systemic lupus erythematosus and antiphospholipid syndrome [3].

Nephrotic syndrome (NS) is defined as proteinuria of > 3 g/day and hypoalbuminemia (<30 g/L). The protein loss leads to loss in Immunoglobulins which predisposes patients to infections. NS is also associated with hypercoagulability and patients are at increased risk of venous thrombosis. The incidence of venous and arterial thromboembolism is low in children occurring in only 2-3% of cases [4]. Only one pediatric case report of thrombosis of the internal jugular vein in a child with NS without any evidence of infection, has been published [5].

CORRESPONDING AUTHOR

Chady El Tawil

(Division of Pediatric Emergency Medicine,
Department of Pediatrics,
Montreal Children's Hospital,
McGill University Health)
ElTawil.chady@gmail.com

A COMPLETE LIST OF THE AUTHORS' AFFILIATIONS
IS AVAILABLE AT THE END OF THE ARTICLE.

SUBMITTED: 25 JAN 2023
REVISED: 24 FEB 2023
ACCEPTED: 10 APRIL 2023

© 2023 THE AUTHOR(S).
PUBLISHED BY NEW HEALTH CONCEPT
PANORAMAOEM.CLOUD

Copyright: This is an Open Access article, distributed under the terms of the Creative Commons Attribution 4.0 International license (<https://creativecommons.org/licenses/by/4.0>, which permits unrestricted re-use, distribution, and reproduction in any medium, provided the original work is properly cited.

How to cite this paper? El Tawil C, Alabdulraheem A, Kilmartin K, Seguin J. Lemierre Syndrome in a Pediatric Patient with Nephrotic Syndrome: A Case Report. *Panorama of Emergency Medicine*. 2023,1(1) <https://doi.org/10.26738/POEM.2023.CT.CR.1>

After a literature review using MeSH and keywords (Lemierresyndrome, NS, thrombophlebitis) in PubMed, we report the first case of LS, to our knowledge, occurring in a child with NS on immunosuppressive therapy.

CASE PRESENTATION

11-year-old boy, known for NS treated with Tacrolimus, presented for headache and neck pain of 2 weeks duration with decreased oral intake and urine output. He had previously sought medical attention twice but was diagnosed with muscular neck sprain and discharged home. His symptoms progressed and he was brought to the emergency department. At triage, the patient was in severe pain, appeared uncomfortable and was found to have a stiff neck. He was afebrile and his vital signs were normal.

On further history and physical exam, the boy looked tired and was complaining of occipital headache and sore throat. The patient had a muffled voice and right sided peritonsillar swelling. Laboratory tests showed a white blood cell count of 14100 cells/microliter with 82.9% neutrophils, high C-Reactive Protein of 122 mg/L (12.2 mg/dL) and 0.3 g/L of protein in the urine, the other tests including electrolytes were normal. Computed tomography angiogram was obtained and showed a large retropharyngeal abscess with acute thrombosis of the proximal third of the right intrajugular vein (**Figure 1**).

The patient was started on piperacillin tazobactam and sent to the operation room for emergent drainage. After the drainage, the patient was started on anticoagulation, but his stay was complicated by reformation of the abscess that required repeat incision and drainage. He was discharge home on day 8 of admission with close follow up with ENT.

DISCUSSION

We describe the first known case of LS in a patient with NS. Despite reduction in mortality from LS with antimicrobial therapy [6], there are reports of increasing rates of *F necrophorum* infections [1] and clinicians need to be aware of this aggressive infection as early diagnosis and therapy is critical. There are several published case studies over the past years that report cases of LS in previously healthy individuals and associated thrombosis in different sites, including lungs, bones, and brain. Also, LS was described in patients with different medical conditions including systemic lupus erythematosus, different types of arthritis among others [7, 8]. The emergency physician should have a low threshold for LS in any patient with such conditions presenting with neck pain, sore throat, fever, or high inflammatory markers to the emergency department.

KEY MESSAGES

What is already known on this topic – Nephrotic syndrome is a thrombophilic condition and Lemierre syndrome is a rare complication of head and neck infections.

What this study adds – We report the first case of Lemierre syndrome, to our knowledge, occurring in a child with nephrotic syndrome on immunosuppressive therapy.

How this study might affect research, practice, or policy – Patients of immunotherapy and with nephrotic syndrome might be at a higher risk of developing Lemierre syndrome.

LS has been reported in all ages, but approximately 70% of the documented cases were in adolescents and young adults between 16–25 years old. Typically, patients present with infection in the oropharynx, fever, neck stiffness, cervical lymphadenopathy which invades the lateral pharyngeal space leading to serious complications.

Fusobacterium necrophorum is the most common cause of LS. It is an anaerobic, nonmotile, pleomorphic, gram-negative bacillus that exists in normal oral flora. It becomes pathogenic when there is a break in the oral mucosa with infections such as pharyngitis.

The pathophysiology of the thrombotic events in LS remains unclear. Some studies attribute it to underlying inherited thrombophilia whereas in other cases, it is believed to be caused by a cascade of enzymes triggered by the bacteria. The thrombotic process caused by *fusobacterium* is multifactorial. Like any thrombosis event, it is mainly the result of Virchow's triad: systemic hypercoagulability, venous stasis by vessel occlusion caused by inflammation, and endothelial damage by the direct endovascular invasion of the bacteria.

F necrophorum consists of multiple virulence factors, including lipopolysaccharide endotoxin, leucocidin, hemolysin, lipase, hemagglutinin, and a cytoplasmic toxin, all contribute to the thrombotic process. These enzymes may produce endothelial damage and diffuse intravascular coagulation by promoting platelet aggregation in an anaerobic environment, which also permits *F necrophorum* to grow [9].

In our case, the patient is known for NS, he was at higher risk of developing complications of LS. As it is commonly known, NS is defined by increased urinary protein losses, edema, hypoalbuminemia, hyperlipidemia, and can be complicated by infectious and thromboembolic manifestations.

The pathogenesis of platelet hyperaggregability and its association with NS has been widely reported throughout the years.

It is reported that hypoalbuminemia leads to increased thromboxane A2 production in platelets,

which trigger platelet aggregation. Also, increased levels of low-density lipoprotein may induce platelet aggregation [4].

Patients with NS characteristically lose plasma proteins in the urine (factors IX, X, and XII, prothrombin, antithrombin, and 2-antiplasmin), which inhibit the systemic hemostasis. On the other hand, high molecular weight proteins are exceedingly synthesized and primarily promote thrombosis. These proteins include factor V, factor VIII, von Willebrand factor, fibrinogen, and 2-macroglobulin accumulate. Factor VII has an essential role in starting the coagulation cascade. It is shown that increased factor VIII led to an increase in the risk factor for thromboembolism in nephrotic patients [10].

So, with all these factors, a patient with NS is at higher risk for all kinds of thrombotic events, especially that our patient was also on immunosuppressive

therapy which can explain his late presentation and the absence of fever.

CONCLUSION

We describe a case of LS in a child with NS. LS is a rare disease that has a high morbidity and mortality if not diagnosed and treated early. Patients with NS are at higher risk for thrombotic event including thromboembolism of the internal jugular vein. A low level of suspicion in those patients can lead to timely diagnosis and early treatment.

KEYWORDS

NEPHROTIC SYNDROME, LEMIERRE SYNDROME, PEDIATRIC EMERGENCY MEDICINE, CASE REPORT

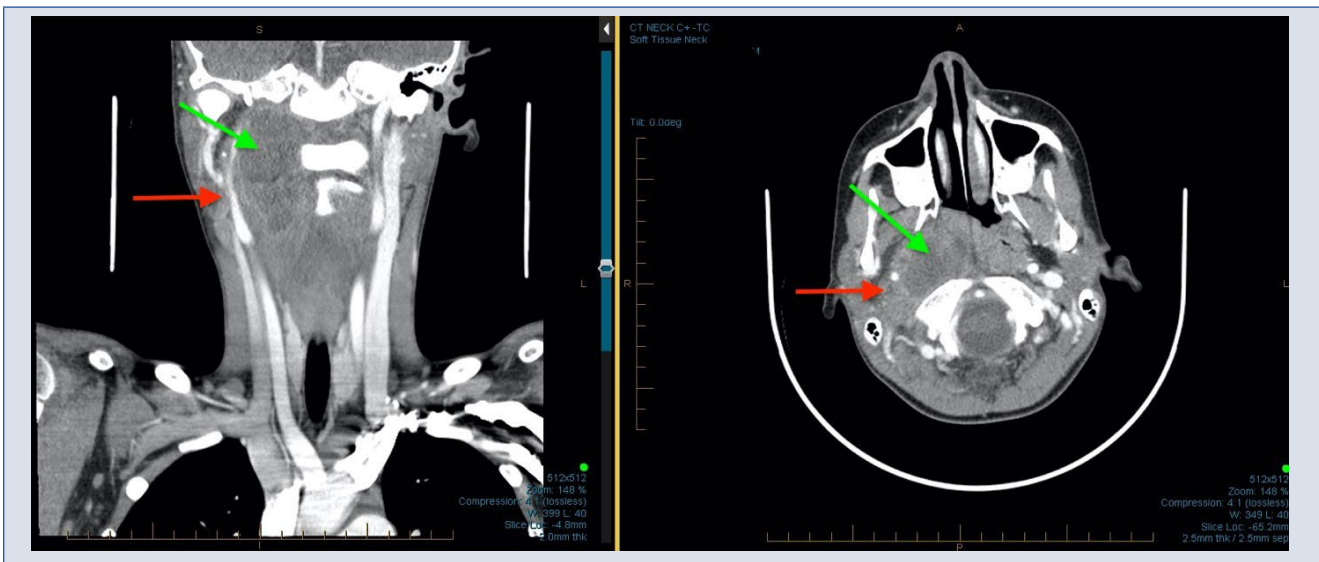


FIGURE 1 - Computed tomography angiogram of the patient showing a large retropharyngeal abscess (green arrow) with acute thrombosis of the right intrajugular vein (red arrow)

AUTHORS' DETAILS

1. Division of Pediatric Emergency Medicine, Montreal Children's Hospital, McGill University Health Centre, Montreal, Canada
2. Department of Pediatrics, Montreal Children's Hospital, McGill University Health Centre, Montreal, Canada
3. Division of Neonatology, Montreal Children's Hospital, McGill University Health Centre, Montreal, Canada

AUTHOR CONTRIBUTIONS

All authors contributed equally and validated the final version of record.

DECLARATIONS

CONFLICTS OF INTERESTS

The Authors declare that there is no conflict of interest.

FUNDING

This research received no specific grant from any funding agency in the public, commercial, or not-for-profit sectors.

REGISTRATION

No registration applicable

DATA AVAILABILITY STATEMENT

The data that support the findings of this study are available from the corresponding author upon reasonable request.

ETHICAL APPROVAL

Ethical approval for this study was not required.

REFERENCES

1. Ramirez S, Hild TG, Rudolph CN, Sty JR, Kehl SC, Havens P, et al. Increased diagnosis of Lemierre syndrome and other *Fusobacterium necrophorum* infections at a Children's Hospital. *Pediatrics*. 2003;112(5):e380. <https://doi.org/10.1542/peds.112.5.e380>
2. Lu MD, Vasavada Z, Tanner C. Lemierre syndrome following oropharyngeal infection: a case series. *J Am Board Fam Med*. 2009;22(1):79-83. <https://doi.org/10.3122/jabfm.2009.01.07024>
3. Cho YP, Choi SJ, Jung BH, Hwang JW, Han MS, Kim YH, et al. Lemierre's syndrome in a patient with antiphospholipid syndrome. *Ann Vasc Surg*. 2006;20(2):274-7. <https://doi.org/10.1007/s10016-006-9004-4>
4. Kerlin BA, Ayoob R, Smoyer WE. Epidemiology and pathophysiology of nephrotic syndrome-associated thromboembolic disease. *Clin J Am Soc Nephrol*. 2012;7(3):513-20. <https://doi.org/10.2215/cjn.10131011>
5. Vyas V, Kapoor S, Panda M, Mandal Ravi RN. Thrombosis of internal jugular vein in nephrotic syndrome presenting as neck pain. *Indian J Pediatr*. 2012;79(10):1388. <https://doi.org/10.1007/s12098-012-0705-0>
6. Screatton NJ, Ravenel JG, Lehner PJ, Heitzman ER, Flower CD. Lemierre syndrome: forgotten but not extinct--report of four cases. *Radiology*. 1999;213(2):369-74. <https://doi.org/10.1148/radiology.213.2.r99nv09369>
7. Fujii T, Iwabuchi Y, Moriyama T, Uchida K, Nitta K. A case of Lemierre syndrome combined with a suspected systemic lupus erythematosus flare. *SAGE Open Med Case Rep*. 2019;7:2050313X19871782. <https://doi.org/10.1177/2050313X19871782>
8. Hagiya H, Haruki Y, Otsuka F. Lemierre syndrome involving external jugular vein. *Acute Med Surg*. 2015;2(1):64-8. <https://doi.org/10.1002/ams2.61>
9. Tan ZL, Nagaraja TG, Chengappa MM. *Fusobacterium necrophorum* infections: virulence factors, pathogenic mechanism and control measures. *Vet Res Commun*. 1996;20(2):113-40. <https://doi.org/10.1007/bf00385634>
10. Cristina L, Benilde C, Michela C, Mirella F, Giuliana G, Gualtiero P. High plasma levels of factor VIII and risk of recurrence of venous thromboembolism. *Br J Haematol*. 2004;124(4):504-10. <https://doi.org/10.1046/j.1365-2141.2003.04795.x>