



## Post-COVID-19 Kawasaki-Like Vasculitis and Endocarditis: A Case Report

Hilal Abdessamad<sup>1</sup>, Charbel Saad<sup>2</sup>, Tarek Abou Saad<sup>3</sup>, Shaza Mortada<sup>4</sup>, Sarkis Ejbeh<sup>5</sup>,  
Richard Zalloum<sup>3</sup>, Rola Husni<sup>1</sup>, Jacques E. Mokhbat<sup>1</sup>

### ABSTRACT

#### BACKGROUND

Coronavirus Disease of 2019 (COVID-19) has a plethora of symptoms that can affect multiple organ-systems, from mild upper respiratory infection symptoms to severe tissue inflammation like myocarditis and vasculitis that are life-threatening and hard to treat in adults.

#### CASE PRESENTATION

A 32-year-old male presents with a fever of unknown origin for a period of 3 months post SARS-CoV-2 infection. He was found to have endocarditis and underwent an aortic valve replacement that was complicated by an aortic aneurysm, needing another surgery. The fever and aneurysm remitted after a new COVID-19 infection and the patient underwent a Bentall procedure with reimplantation of the coronary arteries.

#### DISCUSSION

Cardiac complications of COVID-19 can range from small to large arteritis, valvopathy and aortic aneurysms, which can have significant morbidity and mortality, leading to the need of surgery and prolonged treatment. The scarcity of such cases makes reporting imperative so that clearer guidelines of management can be established.

#### CONCLUSION

Cardiovascular complications of COVID-19 remain the scariest and the least reported, which necessitates the presence of more evidence of their management, which can be lifesaving.

### CORRESPONDING AUTHOR

**Hilal W. Abdessamad**

(Department of Internal Medicine, Division of Infectious Diseases, Lebanese American Gilbert and Rose-Marie Chagoury School of Medicine and the University Medical Center-Rizk Hospital, Achrafieh, Lebanon)

[hilal.abdessamad@gmail.com](mailto:hilal.abdessamad@gmail.com)

A COMPLETE LIST OF THE AUTHORS' AFFILIATIONS  
IS AVAILABLE AT THE END OF THE ARTICLE.

SUBMITTED: 19 APRIL 2024

REVISED: 24 JUNE 2024

ACCEPTED: 30 AUG 2024

© 2024 THE AUTHOR(S).

PUBLISHED BY NEW HEALTH CONCEPT

PANORAMA.OEM.CLOUD

**Copyright:** This is an Open Access article, distributed under the terms of the Creative Commons Attribution 4.0 International license (<https://creativecommons.org/licenses/by/4.0>, which permits unrestricted re-use, distribution, and reproduction in any medium, provided the original work is properly cited.

**How to cite this paper?** Abdessamad H, Saad C, Abou Saad T, Mortada S, Ejbeh S, et al. Post-COVID-19 Kawasaki-Like Vasculitis and Endocarditis: A Case Report. *Panorama of Emergency Medicine*. 2024,2(1) <http://doi.org/10.26738/poem.v2i1.30>

## INTRODUCTION

COVID-19 usually presents as upper respiratory infections and pneumonias triggering an inflammatory cascade that can be prolonged, in what is known as long COVID. This can manifest as autoimmune diseases, neurologic illness, cardiovascular disorders and others. [1, 2] The surplus of complications this viral infection can cause is unique, but its vascular complications are the most mortal, causing acute endothelial dysfunction driven by inflammation, leading to tissue ischemia [3]. Nevertheless, very few data with weak evidence exist on managing such conditions.

These complications can range from small to medium vasculitis all the way to aortitis, aortic valvopathy and aortic aneurysms causing acute myocardial ischemia and severe congestive heart failure (CHF) [4]. They can be self-limiting over a few weeks, or life-threatening, requiring emergent intervention that can range from anticoagulation and control of the inflammatory storm, to intra-vascular or surgical intervention [5].

In this case report, we present a 32-year-old male who had a Kawasaki-like vasculitis after his COVID-19 infection, that was complicated with aortitis, aortic valve inflammation and thoracic aortic aneurysm that required three surgeries and a long treatment duration. To our knowledge, such a case has never been described, which proves the importance of reporting.

## CASE PRESENTATION

### FIRST ADMISSION

On 24/03/22, Mr. FK, a 32-year-old patient presented to our clinic for fever without focus. 3 months ago, he had COVID-19 infection, after which the fever never resolved, with fatigue, weight loss, and lower extremity weakness. He is previously healthy with no significant medical, surgical or travel history. He has a no significant family history of chronic disease.

He was admitted for workup at another institution 1 month prior where he took 2 courses of Augmentin and Levofloxacin without improvement. The workup included negative blood cultures, and negative tests for HIV, syphilis, hepatitis B and C, brucella and tuberculosis, with negative anti-nuclear antibodies (ANA). FK has received the Pfizer mRNA COVID vaccine twice, 2 weeks apart a few months back with no complications.

Upon initial physical examination, he was febrile (38C) and tachycardic (110 BPM). Cardiac auscultation showed a holosystolic murmur in the aortic area. Lower extremities showed mild atrophy.

The patient trans-thoracic echocardiography (TTE) showed a vegetation of the aortic valve with severe regurgitation (Figure 1), hence he was admitted for infectious endocarditis. Blood cultures were taken, and he was started on penicillin and gentamycin. Blood

cultures and brucella, salmonella and coxiella serologies were negative. A complete autoimmune workup was also negative except for beta-2 glycoprotein.

On 27/3/22, he complained of dyspnea and a chest x-ray showed mild congestion, managed by furosemide and oxygen. Shortly after, he had sudden dyspnea with hypotension, desaturation and rapidly progressing cardiogenic shock. Repeat TTE showed acute decompensated right heart failure and pulmonary congestion. He underwent emergency bioprosthetic aortic valve replacement.

Intraoperatively, multiple coronary artery aneurysms were seen. The aortic valve was almost non-existent, extensively eroded without vegetations. It was replaced by a bovine valve. Coronary artery bypass grafting (CABG) could not be performed due to high mortality risk.

Valve cultures were negative, and pathology showed neutrophilic infiltration. The diagnosis of non-infectious endocarditis and Kawasaki-like vasculitis was made based on the gross vascular findings and pathologic evaluation, and he was discharged on Prednisone 1 mg/kg/day taper and followed up in an out-patient setting.

### SECOND ADMISSION

Three months later, the patient presented to the ED for severe chest pain. Four days prior, he was having flu-like symptoms for which COVID-19 PCR tested positive.

He was found to have an anterior ST elevation myocardial infarction. A TTE showed septo-apical dyskinesia with severe dilatation of the aortic root. He received a loading dose of heparin and coronary angiography was performed (Figure 1). It showed a LAD stenosis and total occlusion of the diagonal artery. CT-Angio scan of the chest (Figure 2) showed an ascending aortic aneurysm of 7.3 cm diameter. TTE showed a severe dilatation of the sinus of Valsalva.

Cardiothoracic surgery were consulted, and an aortic root replacement was recommended. He was started on methylprednisolone pulse therapy followed by dexamethasone 6 mg daily. He also received 6mg/kg IV tocilizumab (600 mg) and IV immunoglobulins (IVIG) 3g/kg once to halt the inflammatory reaction. For fever in immunosuppression, he was covered with remdesivir, meropenem and vancomycin.

On 28/7/22, the patient underwent aortic aneurism repair. CABG was not performed because of high risk of rupture. Cultures of the ascending aorta were negative again, and pathology showed neutrophilic infiltration.

The patient was discharged on prednisone, mycophenolate mofetil and a prophylactic dose of trimethoprim/sulfamethoxazole.

### THIRD ADMISSION

The patient re-presented on 16/11/22 for chest discomfort with high grade fever, cough, and hemoptysis. He was found to be hypotensive to 80/60

mmHg and with elevated inflammatory markers. Due to his immunosuppressed status, hypotension and fever, he received meropenem, vancomycin and voriconazole to cover for a possible sepsis. Besides, due to his known history of on-going vasculitis affecting the coronary vessels and aortic root, he was started on tocilizumab and IVIG. His diagnosis was a demand myocardial ischemia with cardiogenic shock, the reasons behind this to be investigated, with highest suspicion of recurrence of the vasculitis.

On 19/11/22, his condition deteriorated again and TTE that showed severe mitral regurgitation and EF of 30%, with an aortic root aneurysm and prosthetic valve dehiscence with regurgitation. He underwent an emergent Bentall procedure and reimplantation of coronary arteries, replacing the bioprosthetic valve (**Figure 3**) with a metallic one. He recovered well and was placed on Prednisone taper again with daily baricitinib and clinical follow-up. Afterwards he was doing well and returned to supervised physical activity.

On September 15th, 2023, the patient passed away of sudden onset ventricular fibrillation while at home.

## DISCUSSION

The case provides a rare depiction of a serious complication of COVID-19 infection, systemic vasculitis. At the time of the diagnosis, no clear management guidelines existed, therefore we extrapolated from what was known previously. COVID-19 infection overdrives the immune system, triggering a wide array of inflammation such as vasculitis [6]. It can trigger B and T lymphocytes, leading to cytokine release and vascular injury [7].

Kawasaki vasculitis affects medium-sized arteries in children and is linked to viral infections. Since the emergence of COVID-19, Multisystem Inflammatory Syndrome in Children (MISC) emerged, which had a similar presentation [8]. MISC can present with cardiac manifestations, muco-cutaneous involvement and refractory fever [9].

Many systemic reviews and case series then started studying vasculitis post COVID-19 infection, but in almost all, Kawasaki-like disease was only described in children. These findings, caused by COVID-19 usually present as a remitting fever with rashes, lymphadenopathy and mucosal lesions, diagnosed by biopsy. The prognosis in children is usually good with steroids and/or IVIG [10]. Such a condition was never described in adults before. A systemic review published in France in 2020 state that it can be seen in African-French descent and is associated with self-limiting multi-system inflammation [11]. In January 2022, Elouardi et al described a very similar presentation in a 28 year-old female who succumbed due to severe myocardial damage due to inflammation and coronary

artery disease and aneurysms due to a Kawasaki-like vasculitis after infection with COVID-19 [12].

The involvement of large arteries has been rarely described. By February 2022, only 4 case reports were published about it [13]. Aortitis can also be caused in the early viremic phase, where the viruses attack the endothelium, causing vasa vasorum intramural thrombosis [14]. This can progress to myocarditis or to CHF, such as in our patient [4]. No treatment guidelines for this condition exist. Data is mostly provided through case reports. A course of steroid taper has been suggested, in combination with other immunomodulatory agents, JAK inhibitors and IVIG [6].

It is worth mentioning that there are reported cases of prolonged fever after COVID-19 vaccination itself, which presents as a chronic dysautonomia and fatigue [15]. There are also cases of multi-system inflammation following the vaccine, which are a very rare entity [16]. However, such an augmented inflammatory response is mostly reported post-COVID infection rather than vaccination, and in the case of our patient, the symptoms started after an infection. In addition, the exacerbation of his symptoms in the second admission were directly after a re-infection. He did not have any complications after he took his vaccines.

Our patient presentation remains a unique one. He had a plethora of complications that were never described together. His presentation is a MISC-like reaction in an adult male, refractory to treatment. He had relapsed arteritis and valvopathy with every new infection. Reporting this case can shed light on the complications and treatment options for post-viral vasculitis considering scarce data with the subject.

## CONCLUSION

COVID-19 has a variety of complications which can affect almost any organ in the body. Cardiovascular complications remain the rarest, yet the deadliest. Our patient had coronary vasculitis, aortitis and inflammatory aortic valve infiltration which were recurrent with every new COVID-19 infection he had, leading to 3 distinct open-heart surgeries. This is why reporting every case with such complications is crucial, to raise the possibility of clustering them into larger studies, that would provide more robust evidence-based data on managing such conditions.

## KEYWORDS

**COVID, VASCULITIS, KAWASAKI, INFLAMMATION, ARTERITIS, SURGERY**

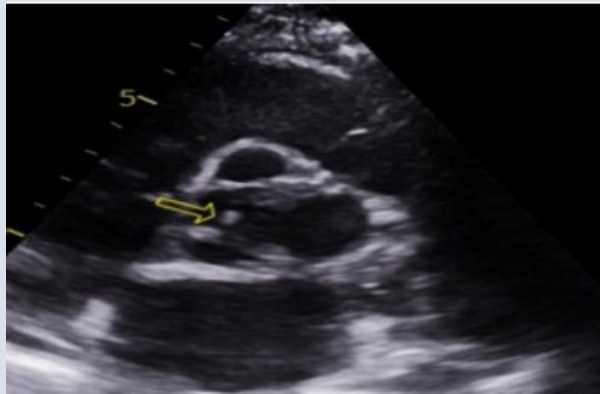


FIGURE 1

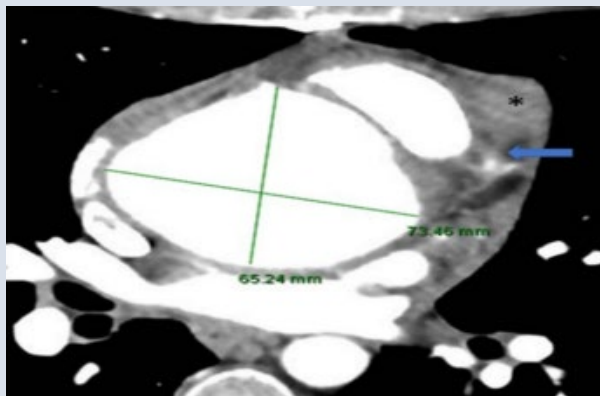


FIGURE 2

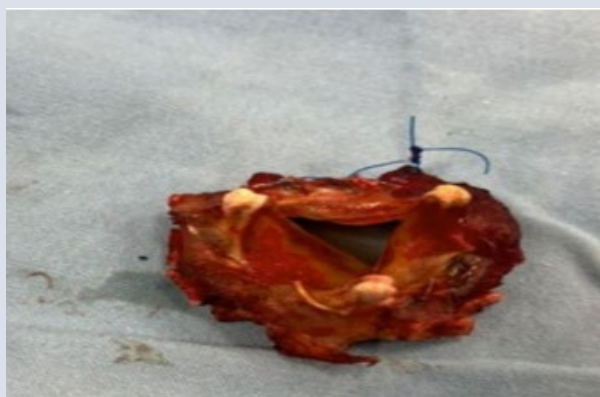


FIGURE 3

## AUTHORS' DETAILS

1. Department of Internal Medicine, Division of Infectious Diseases, Lebanese American Gilbert and Rose-Marie Chagoury School of Medicine and the University Medical Center-Rizk Hospital, Achrafieh, Lebanon.
2. Gilbert and Rose-Marie Chagoury School of Medicine, Lebanese American University, Byblos, Lebanon.
3. Department of Internal Medicine, Division of Cardiology, Lebanese American Gilbert and Rose-Marie Chagoury School of Medicine and the University Medical Center-Rizk Hospital, Achrafieh, Lebanon.
4. Department of General Surgery, Lebanese American Gilbert and Rose-Marie Chagoury School of Medicine and the University Medical Center-Rizk Hospital, Achrafieh, Lebanon.
5. Department of Cardiothoracic Surgery, Lebanese American Gilbert and Rose-Marie Chagoury School of Medicine and the University Medical Center-Rizk Hospital, Achrafieh, Lebanon.

## AUTHOR CONTRIBUTIONS

All authors contributed equally and validated the final version of record.

## DECLARATIONS

## CONFLICTS OF INTERESTS

The Authors declare that there is no conflict of interest.

## FUNDING

This research received no specific grant from any funding agency in the public, commercial, or not-for-profit sectors.

## REGISTRATION

No registration applicable.

## DATA AVAILABILITY STATEMENT

The data that support the findings of this study are available from the corresponding author upon reasonable request.

## ETHICAL APPROVAL

The work presented in this article goes in accordance with the Declaration of Helsinki in 1964.

The patient's written consent was taken prior to reporting this case..

## REFERENCES

1. Thirkell P, Griffiths M, Waller MD. Management of Coronavirus Disease 2019 (COVID-19) Pneumonia. In: Janes SM, editor. Encyclopedia of Respiratory Medicine (Second Edition) [Internet]. Oxford: Academic Press; 2022. p. 342-9. <https://doi.org/10.1016/B978-0-08-102723-3.00187-6>
2. Liu C, Wu C, Zheng X, Zeng F, Liu J, Wang P, et al. Clinical features and multidisciplinary treatment outcome of COVID-19 pneumonia: A report of three cases. *J Formos Med Assoc.* 2020 Nov;119(11):1702-9. <https://doi.org/10.1016/j.jfma.2020.04.008>
3. Rabaan AA, Al-Ahmed SH, Muhammad J, Khan A, Sule AA, Tirupathi R, et al. Role of Inflammatory Cytokines in COVID-19 Patients: A Review on Molecular Mechanisms, Immune Functions, Immunopathology and Immunomodulatory Drugs to Counter Cytokine Storm. *Vaccines (Basel).* 2021;9(5):436. <https://doi.org/10.3390/vaccines9050436>
4. Rajan R, Jayakumar RB, Al-Jarallah M, Dashti R, Kobablava ZD, Brady PA. Escardio. ESC; 2021 [cited 2023 Jul 27]. COVID-19 and the heart. Available from: <https://www.escardio.org/Journals/E-Journal-of-Cardiology-Practice/Volume-21/covid-19-and-the-heart>
5. Shimada T, Itagaki H, Shirota Y, Endo T. Spontaneous Improvement of Aortitis Associated with Severe COVID-19 Infection—A Case Report. *Medicina [Internet].* 2023;59(5). <https://doi.org/10.3390/medicina59050816>
6. Zebardast A, Hasanzadeh A, Ebrahimian Shiadeh SA, Tourani M, Yahyapour Y. COVID-19: A trigger of autoimmune diseases. *Cell Biol Int.* 2023 May 1;47(5):848-58. <https://doi.org/10.1002/cbin.11997>
7. Christodoulou M, Iatridi F, Chalkidis G, Lioulis G, Nikolaidou C, Badis K, et al. ANCA-Associated Vasculitis May Result as a Complication to Both SARS-CoV-2 Infection and Vaccination. *Life.* 2022;12(7):1072. <https://doi.org/10.3390/life12071072>
8. Woo HO. Recent research trends in Kawasaki disease-related infection. *Clin Exp Pediatr.* 2022 Jul 22;65(11):538-9. <https://doi.org/10.3345/cep.2022.00696>
9. Folga BA, Karpenko CJ, Grygiel-Górniak B. SARS-CoV-2 infection in the context of Kawasaki disease and multisystem inflammatory syndrome in children. *Med Microbiol Immunol.* 2023 Feb 1;212(1):3-12. <https://doi.org/10.1007/s00430-022-00756-3>
10. Wong K, Farooq Alam Shah MU, Khurshid M, Ullah I, Tahir MJ, Yousaf Z. COVID-19 associated vasculitis: A systematic review of case reports and case series. *Ann Med Surg (Lond).* 2022;74:103249. <https://doi.org/10.1016/j.amsu.2022.103249>
11. Toubiana J, Poirault C, Corsia A, Bajolle F, Fourgeaud J, Angoulvant F, et al. Kawasaki-like multisystem inflammatory syndrome in children during the covid-19 pandemic in Paris, France: prospective observational study. *BMJ.* 2020 Jun 3;369:m2094. <https://doi.org/10.1136/bmj.m2094>
12. Elouardi Y, Rebahi H, Zarrouki Y, Ziadi A, Younous S, Samkaoui MA. COVID-19 associated Kawasaki-like multisystem inflammatory syndrome in an adult. *Rev Esp Anesthesiol Reanim (Engl Ed).* 2022 Jan 1;69(1):43-7. <https://doi.org/10.1016/j.redare.2020.11.009>
13. Abu Hassan F, Abu Alhalawa M, Majdoubeh Y, Nepal A, Sufan SS. COVID-19 Aortitis: A Review of Published Cases. *Cureus.* 2022 Feb 15;14(2):e22226. <https://doi.org/10.7759/cureus.22226>
14. Manenti A, Farinetti A, Manco G, Mattioli A. Vasculitis and aortitis: COVID-19 challenging complications. *J Vasc Surg.* 2021 Jan 1;73(1):347-8. <https://doi.org/10.1016/j.jvs.2020.08.029>
15. Semmler A, Mundorf AK, Kuechler AS, Schulze-Bosse K, Heidecke H, Schulze-Forster K, et al. Chronic Fatigue and Dysautonomia following COVID-19 Vaccination Is Distinguished from Normal Vaccination Response by Altered Blood Markers. *Vaccines.* 2023;11(11):1642. <https://doi.org/10.3390/vaccines11111642>
16. Lee SJ, Park DW, Sohn JW, Yoon HJ, Kim SH. COVID-19 Vaccine-Induced Multisystem Inflammatory Syndrome With Polyserositis Detected by FDG PET/CT. *Clin Nucl Med.* 2022;47(5). <https://doi.org/10.1097/RLU.0000000000004094>